

Intratympanic gentamicin for the treatment of Ménière's Disease and other forms of peripheral vertigo

John Carey, MD

*Department of Otolaryngology–Head and Neck Surgery, Johns Hopkins University,
601 North Caroline St., Baltimore, MD 21287, USA*

Few therapies for Ménière's disease or other forms of peripheral vertigo have undergone such dramatic reappraisals as has the use of intratympanic aminoglycosides. Soon after its introduction in 1957, the therapy fell into disfavor because of the high rate of sensorineural hearing loss encountered in the initial studies. Reductions in the frequency of intratympanic administration have improved the preservation of hearing without compromising vertigo control.

This article first reviews the history of intratympanic aminoglycoside treatment since the 1950s, but the reader is encouraged to read the historical article by Dr. Lawrence Lustig for further historical details. Some of the important basic science findings relevant to the delivery and effects of intratympanic gentamicin, indications for treatment, and current treatment protocols and outcomes are reviewed.

History

In 1956 [1] and 1957 [2], Schuknecht reported on the use of intratympanic injections of streptomycin for the treatment of Ménière's disease. He used large daily doses (150–600 mg/day) until 1 day after the appearance of disequilibrium and the loss of caloric responses. Vertigo was controlled in five of eight patients treated (63%), but the same five patients experienced profound sensorineural hearing loss, presumably from the same ototoxic effect on cochlear as on vestibular hair cells. Silverstein [3] also found the rate of hearing loss unacceptably high. Because of this cochleotoxicity, the

E-mail address: jcarey@jhmi.edu

use of intratympanic aminoglycosides fell into relative disfavor, especially in the United States, for 2 decades.

In Germany, Lange [4] revived intratympanic aminoglycoside therapy in the late 1970s. He reported on his experience in the use of intratympanic streptomycin for the treatment of vertigo caused by Ménière's disease in 52 patients. He used an indwelling catheter to administer 0.1 mL of streptomycin sulfate, 0.33 g/mL, every 5 hours, day and night, for 2 days. He reported complete vertigo control in 50 patients (96%), with follow-up for as long as 8 years. Hearing was preserved or improved in 76%, but 24% suffered varying degrees of hearing loss in the treated ear. This experience prompted Lange to recommend intratympanic gentamicin instead, because its cochleotoxicity was believed to be lower than that of streptomycin.

In addition to making the switch to gentamicin, other German colleagues decreased the frequency of intratympanic dosing to decrease the risk of hearing loss. Beck and Schmidt [5] reported on results in 40 patients treated either with intratympanic streptomycin or gentamicin, presumably with the same frequency of dosing, until "the slightest sign of inner ear damage was conceived," as indicated by dizziness, spontaneous nystagmus, or a change in daily audiograms. With this approach, they reported elimination of vertigo in 37 patients (92.5%), but hearing deterioration in only 15%, with no cases of deafness in the treated ear. Katzke [6] administered 16 mg of intratympanic gentamicin daily to an average total dose of 90 mg. He achieved complete vertigo control in 66% of 41 patients and partial control in an additional 17%. This protocol resulted in hearing loss in 34%. Blessing and Schlechter [7] administered daily intratympanic gentamicin until symptoms of cochlear or vestibular intoxication appeared. They reported a similar rate of hearing loss: 33% deterioration in speech discrimination in 82 patients, for whom vertigo control was achieved in 89%.

Other investigators who reduced injections to once per day continued to find hearing losses in the range of 30% to 40%. Moller et al [8] at Boys' Town gave daily intratympanic gentamicin injections to 15 patients with Ménière's disease for 3 to 11 days. All but 1 patient ceased to have vertigo attacks, and caloric sensitivity was lost in each case. Hearing worsened in 5 patients (33%). Odkvist [9] in Sweden followed a similar schedule of daily treatments in 29 patients, all of whom were relieved of vertigo attacks. Those who received more than six doses, however, were at increased risk of hearing loss, which occurred in 11 (38%), including two deaf ears. Laitakari [10] administered one daily dose of intratympanic gentamicin for 3 days, followed by doses given every other day until signs of vestibular hypofunction appeared, giving a median of six injections. Complete control of vertigo was achieved in 12 (60%) of 20 patients, and substantial control in 6 (30%). He noted worsened hearing in 9 (45%) of his 20 patients, with 6 (30%) becoming deaf in the treated ear.

In addition to the risk of sensorineural hearing loss, Laitakari [10] pointed out two other problems with daily intratympanic gentamicin

injections: postablative disequilibrium and vertigo recurrences. Although 90% of the patients found the treatment beneficial, Laitakari emphasized that “disabling” ablative disequilibrium affected many of the patients and caused 6 (40%) of 15 employed patients to seek disability status. Moreover, 2 patients required additional injections for recurrent vertigo after 5 to 8 months of remission.

Nedzelski et al [11–13] continued to use multiple (3 times/day) doses of gentamicin in Toronto, but they buffered the drug to a lower concentration (26.7 mg/mL) and limited therapy to 4 days, or fewer if unsteadiness, nystagmus, or hearing loss developed. Complete control of vertigo was obtained in 83% and substantial control in 17%. Hearing worsened in 27%, with profound hearing loss in 10%. These authors recently updated their findings with long-term (>2 years) follow-up data [14]. With more than 2 years of follow-up, they were able to use the American Academy of Otolaryngology-Head and Neck Surgery’s (AAO-HNS) 1995 guidelines to report vertigo and hearing outcomes [15]. AAO-HNS class A control of vertigo (no vertigo) was achieved in 84%, and class B control (vertigo attacks occurring at 1%–40% of pretreatment rate) in 8%. Hearing worsened in 26% of those followed long term [16].

Magnusson et al [17,18] observed that clinical unsteadiness might not appear for 2 to 3 days after intratympanic gentamicin treatment and therefore suggested that less frequent dosing should be used. The notion of a titration protocol, in which injections were given only once per week until symptoms of ototoxicity appeared, was introduced by Toth and Parnes [19]. They compared a group of 21 patients treated with a “shot-gun” protocol of three injections of buffered gentamicin (26 mg/mL) per day for 4 days to a group of 16 treated with a titration protocol of injections given once per week. The weekly injections continued for 4 weeks or until there was evidence of inner ear damage. Such evidence was derived from audiograms (pure-tone average decrease >15 dB or a decrease in speech discrimination score >15%), patients’ complaints of disequilibrium, or the onset of new spontaneous or post-head shaking nystagmus. They found no difference in vertigo control between the two protocols. “Excellent” or “good” vertigo control was achieved in approximately 80% of the patients in either protocol. Whereas 57% of patients in the shot-gun protocol had worse hearing, and 19% developed a dead ear, only 19% in the titration protocol had hearing deterioration. In four (25%) of the patients in the titration protocol, treatment was halted before 4 weeks because of the interval detection of hearing loss. Notably, each of these four had absent caloric responses on electronystagmography and excellent or good control of vertigo. Atlas and Parnes [20] recently updated the London, Ontario, experience with their titration protocol in a report containing 5-year outcomes in 46 patients. AAO-HNS class A control was achieved in 74%, and class B control in 7%. Eight (17%) had poor vertigo control and required surgical interventions for further treatment (class F). Five-year

audiometric results in 19 of their patients demonstrated hearing worsened by a decline of more than 15 dB in pure tone average in 1 patient (5%) and a decline of more than 15% in speech discrimination score in 1 patient (5%).

Many centers have subsequently adopted titration or low-dose protocols of one form or another. Blakley [21] reviewed the outcomes of multiple trials and found no advantage to daily or multiple-daily dosing. Diamond et al [22] provided the most recent review, which found that multiple daily dosing resulted in vertigo control on average in 96% (range, 75%–100%) and hearing loss in 26% (range, 0–75%). Once-daily dosing protocols yielded vertigo control in 84% (range, 76%–97%) and hearing loss in 32% (4%–45%). Weekly dosing protocols controlled vertigo in 87% (range, 75%–100%) with 21% (range, 0–37%) hearing loss. Thus, multiple-daily dosing may yield slightly better vertigo control, but multiple- or once-daily dosing may also carry a slightly greater risk of hearing loss than weekly dosing schedules. No systematic effects were found for different concentrations of gentamicin (from 10–40 mg/mL) or for different techniques of delivery (by direct needle injection, tympanostomy tube, or catheter).

Basic science

Penetration of the round window membrane

Intratympanic gentamicin probably gains access to the inner ear fluids by uptake through the round window membrane [23]. The outer layer of this trilayer membrane consists of a single sheet of cuboidal cells. Tight junctions between these cells indicate that passive diffusion between the cells is not the likely means of entry of substances from the middle ear. Rather, the numerous mitochondria and well-developed endoplasmic reticulum and Golgi apparatus of these cells suggest that active endocytosis carries drugs such as gentamicin through the membrane [24]. Several factors affect the passage of substances through the round window membrane, including the molecular size and charge of the substance and membrane thickness. Pharmacologic gentamicin preparations consist of three distinct molecules, gentamicin C1, C1a, and C2, with a low mean molecular weight of 466 mg and a positive charge, both of which are favorable for gentamicin's passage [25,26]. The normal human round window membrane is thicker than that of smaller mammals [27]. Nevertheless, Becvarovski et al [28] confirmed the rapid permeability of gentamicin into the inner ear at the round window membrane in humans undergoing labyrinthectomy.

The round window may not always offer adequate access to the inner ear fluids. The thickness of the round window membrane may increase significantly after middle ear inflammation. Hellstrom et al [29] found that the rat round window membrane increased fivefold in thickness after purulent otitis media. The round window niche has been found to be

obstructed by a second “false” membrane in up to 20% of human temporal bones [30,31]. In fact, the temporal bone study by Alzamil and Linthicum [30] found that 22% of individuals had bilateral round window obstruction either by such a membrane or by fat or fibrous tissue. Such obstructions might explain why some patients do not develop vestibular hypofunction or achieve control of vertigo after several attempts at intratympanic gentamicin injection.

Pharmacokinetics in inner ear fluids

In the guinea pig, administration of gentamicin solution to the round window membrane results in a perilymphatic concentration of the drug that is approximately 5% to 10% of that of the applied solution within 90 minutes of a continuous application. Once the drug is removed from the round window membrane, the elimination half-life is only about 75 minutes [26]. Thus, the 30-minute application of intratympanic gentamicin typically used in clinical practice results in a period of only a few hours during which gentamicin is freely present in the perilymph. There is no evidence to suggest that the drug further accumulates in endolymph [32]. Sustained-release vehicles have been proposed as a means of maintaining more prolonged and reliable levels of gentamicin in perilymph [33]. Because gentamicin is actively cleared from the inner ear during the administration, however, large concentration gradients probably develop no matter how long the duration of the exposure, and hair cells of the basal turn of the cochlea probably have the highest exposure to the drug [34]. Gentamicin must pass from the scala tympani to the scala vestibuli to gain access to vestibular hair cells. Experimental evidence from the guinea pig suggests that diffusion around the helicotrema is too slow to explain the observed rate accumulation in the vestibular fluids. Instead, interscalar communication has been suggested as the likely route by which gentamicin reaches the vestibule [25].

Cellular uptake and trafficking

Once aminoglycosides reach the endolymph, these drugs are selectively concentrated in hair cells as well as in support cells [35]. Aminoglycosides may enter the hair cells by one of two routes. The cation channels that are responsible for transduction in the stereocilia are relatively nonselective, and aminoglycosides may be able to enter the stereocilia by these channels [36]. In support of this hypothesis, Steyger et al [37] have recently shown that immunolabeled and fluorescently conjugated gentamicin molecules concentrate in the stereocilia of saccular hair cells in vitro. The second potential route for entry is endocytosis, in which these drugs are actively internalized in vesicles and transferred to the lysosomal compartment [35,38]. Following this process, lysosomal enzymes may be added to these vesicles over time, subsequently leading to swelling and rupture of the vesicles [39]. This

delayed exposure of targets of action in the cytoplasm or nucleus to the drug may be responsible for the delay often seen between gentamicin treatment and the onset of symptoms of vestibular hypofunction [17,18] as well as the observation that gentamicin concentrates in outer hair cells before the development of measurable hearing loss [40]. The sequestration of aminoglycosides in lysosomes that do not rupture may spare some hair cells. The trapped intracellular drug can persist much longer than it does in perilymph, however; the half-life for clearance from hair cells may be 5 to 6 months [41,42].

Effects on hair cells

Aminoglycosides have many potential toxic effects on hair cells. These positively charged molecules may enter the nonselective cationic channels in the stereocilia. In fact, the aminoglycosides block ionic currents through these channels [36]. Thus, even without structural damage the hair cell may cease to transduce stereociliary deflections. A number of characteristic structural changes also accompany aminoglycoside ototoxicity. The stereocilia often fuse, probably because of the loss of their glycocalyx coating and the subsequent adhesion of the plasma membranes between neighboring stereocilia [43]. Aminoglycosides also cause hair cells to balloon out at their apical surfaces and their mitochondria to degenerate. Ultimately, entire hair cells degenerate within the epithelium or are expelled from its luminal surface [44]. Gentamicin causes greater loss of type I than of type II hair cells [45].

Many of the original studies of the effects of aminoglycosides on the inner ear used systemic administration. Studies that have specifically examined the effects of intratympanic gentamicin treatment in animal models also find significant hair cell loss, particularly of type I hair cells [46]. As with systemic aminoglycoside exposure, intratympanic gentamicin results in regionally selective damage in which the central region of the crista and the striola of the macula are preferentially damaged. Semicircular canal cristae show more damage than the otolithic maculae. Significant losses of cochlear hair cells, particularly outer hair cells, are also seen in a dose-dependent manner [47,48]. It has recently become apparent that damage may be limited to only the apical structure of the hair cell, comprising the stereocilia and cuticular plate. These apical specializations may be shed from the cell, leaving a subepithelial basal remnant capable of self-repair [49].

The precise biochemical targets by which aminoglycosides cause these ototoxic effects are not known. Damage may involve binding to plasma membrane phospholipids, inactivation of the enzyme ornithine decarboxylase, or binding to iron and formation of oxygen free radicals [50,51]. Apoptotic mechanisms may be activated, resulting in cell death [52]. Mitochondrial damage is also likely to be a key determinant of hair cell death after aminoglycoside damage [53–56].

Effects on dark cells

The vestibular dark cells are specialized secretory cells located adjacent to the sensory epithelia. They transport potassium from the extracellular environment to the endolymph, creating the high-potassium pool necessary for hair cells to generate their receptor potentials [57]. Their normal morphology is similar to that of ion-transporting cells in the renal tubules and marginal cells in the stria vascularis, with numerous plasma membrane infoldings. Because Ménière's disease is thought to be a disorder of fluid and ion balance in the labyrinth, attention has been directed at the effects of aminoglycosides on these dark cells. Park and Cohen [58,59] examined the effects of high-dose systemic streptomycin in chicks on gross balance and on the dark cells surrounding the crista. With doses of streptomycin of 400 to 1200 mg/kg daily for 15 days, they noted head tremors and poor perching and righting efforts. Morphologically, they noted that dark cell processes retracted and that numerous vacuoles appeared in their cytoplasm. Pender [60] noted similar changes in cat vestibular dark cells with intratympanic gentamicin treatment. Park and Cohen noted no hair cell loss with their large streptomycin doses, however. This negative finding is surprising, given that such doses of streptomycin have subsequently been used by others to create virtually complete hair cell destruction in the chick [61,62]. These latter studies noted that hair cell regeneration could proceed after just a few days of treatment, even in the face of ongoing streptomycin administration. Perhaps Park and Cohen observed regenerated hair cells with their longer course of streptomycin and did not appreciate the damage to hair cells done by streptomycin in the earlier period. Chen et al [48] found little change in dark cell morphology in their study of the effects of intratympanic gentamicin in the chinchilla. The importance of dark cell damage to the control of vertigo in endolymphatic hydrops remains speculative.

Effects on vestibular reflexes

Recent work has identified changes in vestibular reflex function after intratympanic gentamicin treatment in humans. The findings suggest that the toxic effects on hair cells are prominent, even with single doses of intratympanic gentamicin. Carey et al [63] studied vestibular function as measured by caloric tests and by the three-dimensional angular vestibulo-ocular reflexes (AVOR) elicited by rapid rotary head thrusts in the planes of the semicircular canals before and after low doses of intratympanic gentamicin. The head-thrust test relies on Ewald's second law, which specifies that there is a greater effect from excitation of a semicircular canal than from inhibition of a canal [64,65]. When the head is horizontally rotated toward the intact side in the head-thrust test, the horizontal canal on the intact side is excited. The usual—but small—contribution of inhibition from the canal on the lesioned side is missing, but the response (eye velocity) generated by the excited canal is sufficient to yield an AVOR that is

compensatory and only minimally changed. When the head is horizontally rotated toward the lesioned side, however, the horizontal canal on the intact side is inhibited. Without the large excitatory contribution from the horizontal canal on the lesioned side, the asymmetry between excitation and inhibition becomes manifest, and the AVOR is noncompensatory. On clinical examination this noncompensatory AVOR is manifested as a delay in the eye-movement response followed by a rapid, corrective eye movement that brings the eye back to the target, the so-called “refixation saccade.” The head-thrust test has been quantitatively validated using magnetic search coil recordings of eye and head movements. AVOR gain values (the ratio of eye to head velocity) near 1.0 have been demonstrated in normal subjects, and markedly diminished gains have been found for head thrusts toward the side of surgical unilateral vestibular deafferentation (SUVD) after labyrinthectomy or vestibular neurectomy [66,67].

Seventeen subjects with intractable vertigo caused by unilateral Ménière’s disease underwent three-dimensional AVOR testing as well as caloric testing before and after treatment with intratympanic gentamicin [63]. Before treatment the gain asymmetry calculated from the responses to head thrusts exciting the horizontal canal of the affected ear in comparison to the contralateral ear was more than 20% in only two of these subjects. In contrast, caloric asymmetry greater than 20% was noted in 13 of the 17 subjects. Following gentamicin injections (one injection in 12 patients, two injections in 2 patients, and three injections in 3 patients), large decreases in AVOR gains were noted for head thrusts that excited each of the ipsilateral canals. Gains for ipsilesional AVOR responses were reduced by 53% to 61% in comparison to pretreatment values, whereas contralesional responses were reduced by only 9% to 11%. The pretreatment findings provide evidence that patients having attacks of vertigo from active cochleovestibular Ménière’s disease retain nearly normal canal sensitivity to physiologic head movements, even if the caloric responses are diminished. The posttreatment findings provide evidence that as few as one to three injections of intratympanic gentamicin significantly reduce the physiologic function of the semicircular canals.

Fig. 1 shows the representative head velocity (*dashed gray line*) and eye velocity (*solid gray line*) traces for a 38-year-old woman with a 3-year history of episodic vertigo as well as right fluctuating sensorineural hearing loss and tinnitus. Her caloric tests showed a 23% right unilateral vestibular weakness. Each panel of Fig. 1 shows the traces of the subject’s eye and head velocities for head thrusts that excited the indicated canal. For example, the panels in the column labeled “Ipsi” show the AVOR for head thrusts that excited the canals on the side affected with Ménière’s disease. For ease of comparison, the signs of the eye and head velocity traces have been given as positive values in all panels. Fig. 2 shows data from the same subject tested 49 days after a single injection of gentamicin into the right middle ear. Her AVOR data demonstrate marked decrements in the gains

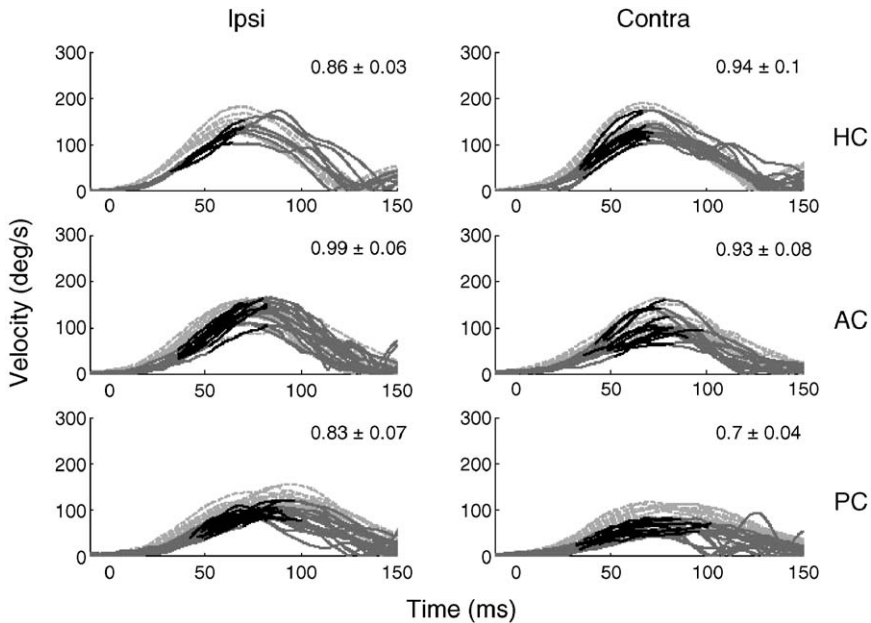


Fig. 1. Responses to head thrusts in a 38-year old subject with right Ménière's disease measured immediately before intratympanic gentamicin treatment. Each panel shows head velocity (*dashed light gray traces*) and eye velocity (*dark gray and black traces*) for rotations in the excitatory direction for each canal. Data from 8 to 12 stimulus repetitions are shown for each canal. Head velocity has been inverted to permit a direct comparison of the stimulus and the response. The interval over which gain was analyzed (30 milliseconds before peak head velocity) is shown in black for each trace. The eye velocity before and after this analysis interval is shown in dark gray. A gain value was calculated as eye/head velocity for every point in time during the analysis interval. The response gain for each stimulus repetition was defined as the maximum gain value during the interval of analysis. The response gain (mean \pm SD for all stimulus repetitions) is given in the upper right corner of each panel. *Abbreviations:* AC, anterior canal; HC, horizontal canal; PC, posterior canal.

for head thrusts that excited any of the treated canals. Her AVOR gains for excitation of the contralateral canals also changed, but much less so. Her vertigo was controlled after the single dose. Following gentamicin treatment, her caloric tests showed a 92% unilateral vestibular weakness on the right side.

During the 6 months immediately following treatment with intratympanic gentamicin, 16 of the 17 subjects in the study of Carey et al [63] experienced no episodes of vertigo. The 1 patient who did experience episodes of vertigo received two additional gentamicin injections in the affected ear, at which point her vertigo was controlled. AVOR testing in this patient revealed no decrease in gain for canals on the treated side after the first intratympanic gentamicin injection. When tested after the third injection, ipsilesional gains were decreased and were comparable to those measured for ipsilesional responses in the other patients after gentamicin.

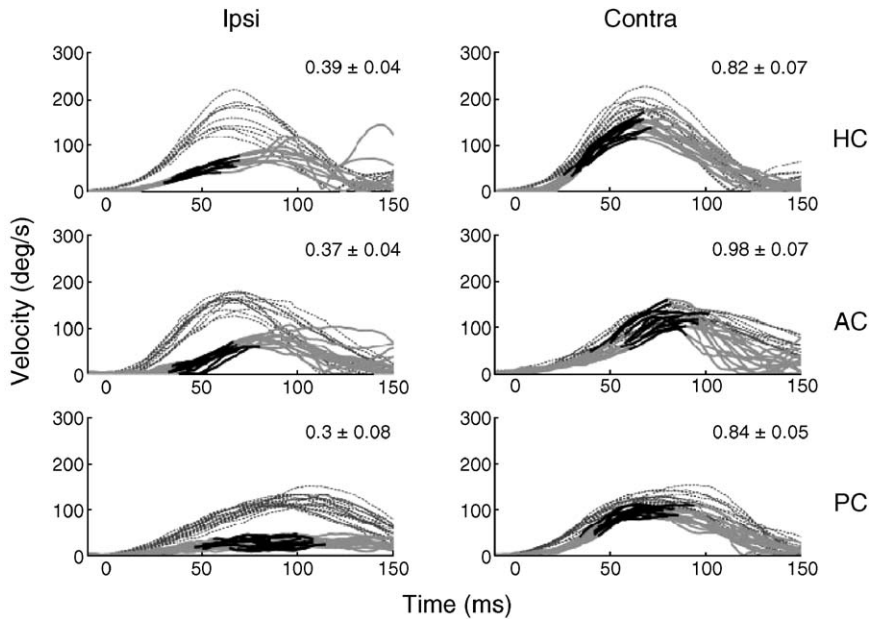


Fig. 2. Responses to head thrusts that excited each of the six semicircular canals in the same subject as in Fig. 1 measured 49 days after a single intratympanic injection of gentamicin. Panels, traces, and gain values are as described for Fig. 1.

These findings indicate that control of vertigo is linked to reduction in vestibular function on the treated side.

AVOR gains for head thrusts that excited canals on the gentamicin-treated side exceeded those seen for the same stimuli in subjects with SUVD, and gain asymmetries were smaller after gentamicin than after SUVD. This finding indicates that intratympanic gentamicin does not produce a complete loss of vestibular function on the treated side. Preservation of spontaneous afferent firing rate or of some rotational sensitivity on the gentamicin-treated side may account for the differences between subjects after intratympanic gentamicin and subjects after SUVD.

Candidates for intratympanic gentamicin therapy

Patients with Ménière's disease

Patients with unilateral Ménière's disease who have not responded to conservative medical management for example, with sodium restriction and diuretic therapy, are candidates for intratympanic gentamicin treatment. The risk of hearing loss previously dissuaded some practitioners from recommending intratympanic gentamicin treatment before or instead of

endolymphatic sac surgery. Titration protocols, however, have resulted in lower rates of hearing loss. Moreover, the benefit of endolymphatic sac surgery remains questionable [68]. In addition, patients who have had prior endolymphatic sac surgery frequently do not respond as well to intratympanic gentamicin treatment as those who have had no prior ear surgery, perhaps because of changes in the round window niche or membrane [69]. Many practitioners offer intratympanic steroid injections as a nondestructive option before intratympanic gentamicin treatment for unilateral Ménière's disease [70–72].

Patients with bilateral Ménière's disease present a special management difficulty. Systemic (intramuscular) streptomycin has been recommended as a means of controlling vertigo by inducing bilateral vestibular hypofunction. Systemic streptomycin, however, can produce chronic disequilibrium and oscillopsia, which can be disabling, in up to half of patients [73,74]. Pyykko et al [75] reported on 14 patients with bilateral Ménière's disease whom they treated with bilateral intratympanic gentamicin injections. Vertigo was eliminated in 11 patients and controlled in 3, with no significant change in hearing. Only 3 patients had enough ongoing disequilibrium to prevent return to work. The role of intratympanic gentamicin in the treatment of bilateral Ménière's disease will undoubtedly be further explored in this challenging group of patients.

Patients with other forms of peripheral vertigo

Brantberg et al [76] have reported on the use of intratympanic gentamicin to relieve vertigo in patients with peripheral disorders other than Ménière's disease. Vertigo attacks in patients with deaf ears and after sudden idiopathic sensorineural hearing loss were successfully treated. Disabling benign paroxysmal positioning vertigo not responsive to canalith repositioning and vertigo caused by a medium-sized acoustic neuroma in an elderly patient were also treated.

The role of titrated intratympanic gentamicin therapy may expand for the treatment of vertigo not caused by Ménière's disease. However, the otolaryngologist using intratympanic gentamicin must be confident that the source of vertigo is the labyrinth before proceeding with intratympanic gentamicin treatment. Episodic vertigo has a number of causes, not all of which are peripheral vestibular disorders. Recent literature has emphasized the role of migraine as a cause of episodic vertigo [77,78]. It is important to distinguish this neurologic condition from purely peripheral forms of vertigo, because a labyrinthine-destructive treatment may not address the underlying problem and may cause the patient further difficulties related to unilateral loss of vestibular function. Unilateral sensorineural hearing loss, caloric weakness, absent or reduced vestibular-evoked myogenic potentials, and electrocochleographic abnormalities may help assure that the labyrinth is the source of vertigo. Even when Ménière's disease can be confidently

diagnosed, however, migraine may still complicate the picture. The lifetime incidence of migraine in patients with Ménière's disease has been found to be as high as 56%, significantly higher than in orthopedic control patients [79]. This high co-incidence suggests a possible link between Ménière's disease and migraine. Recent work suggests that the inner ear may be a target of neurogenic inflammation caused by trigeminal nerve activation as occurs in migraine [80]. Damage from this inflammation may cause hydrops and Ménière's disease. In the author's experience, patients with both Ménière's disease and migraine do best when migraines are optimally managed with dietary and lifestyle modifications and, if necessary, migraine prophylactic medications, before undertaking intratympanic gentamicin treatment.

Treatment protocols

Many centers now use a titration protocol, giving injections no more often than once per week and halting when some measure of vestibular function is reduced, vertigo is controlled, or hearing worsens. Long-term vertigo control with such protocols does not significantly differ from the control achieved with daily doses or multiple doses daily [22,81]. Likewise, there is no evidence that use of a tympanostomy tube, microcatheter, or other delivery device has any benefit over simple direct injection with a small-gauge needle through the anesthetized eardrum.

The procedure can thus be simplified to an outpatient clinic visit in which the tympanic membrane is anesthetized with phenol or other topical pretreatment. A long 25-gauge needle is used to make two micro-myringotomies. One in the anteroinferior quadrant serves as a pressure relief hole. The second is placed over the round window niche to assure placement of the drug solution against the round window. Buffered gentamicin reduces the burning sensation that patients may experience. The intravenous preparation of 40 mg/mL gentamicin is buffered with sterile 8.4% sodium bicarbonate to a final pH of 6.4 and concentration of 26.7 mg/mL [14]. Some practitioners use low concentrations of lidocaine in the injection to further reduce pain. The volume injected must be adequate to bathe the round window membrane; usually 0.4 to 1 mL suffices. The patient is placed supine with the head turned to the contralateral side for the injection. The patient maintains this position, and the head of the bed is angled slightly down for 30 minutes after the injection. Excess solution is then aspirated from the canal, and the patient is instructed to keep the ear dry for 2 weeks. A patch is not routinely placed, and the risk of persistent tympanic membrane perforation is low.

The patient can be seen in follow-up in 1 to 3 weeks. If there is evidence of new vestibular hypofunction in the form of spontaneous nystagmus, post-head shaking nystagmus, or a head-thrust sign, the injections are stopped. Otherwise, repeat injections are given every 1 to 3 weeks until such

signs appear, vertigo is controlled, or hearing loss develops. When these guidelines were used at Johns Hopkins, vertigo was completely controlled (class A) in 90% of 34 patients, and hearing worsened in 17% (profoundly in only 3%) [82]. Recurrent vertigo developed in 10 patients (29%) from 4 to 15 months after initial complete control, but this recurrent vertigo responded well to additional intratympanic gentamicin injections without changes in hearing. These findings are representative of those from other titration protocols [22,81].

Summary

Titration therapy with intratympanic gentamicin offers class A or B control of vertigo in 87% (range, 75%–100%) of patients with unilateral Ménière's disease. The risk of additional hearing loss is about 21% (range, 0–37%) [22]. Vertigo may recur, however, in nearly one third of patients over time. These recurrences can also be treated by intratympanic gentamicin with a similar risk of hearing loss. The salient effect of intratympanic gentamicin is probably the reduction of vestibular function through damage to hair cells, but a complete ablation of function does not seem to be necessary for vertigo control.

References

- [1] Schuknecht HF. Ablation therapy for the relief of Meniere's disease. *Laryngoscope* 1956; 66(7):859–70.
- [2] Schuknecht HF. Ablation therapy in the management of Meniere's disease. *Acta Otolaryngol Suppl (Stockh)* 1957;132:1–42.
- [3] Silverstein H. Streptomycin treatment for Meniere's disease. *Ann Otol Rhinol Laryngol Suppl* 1984;112:44–8.
- [4] Lange G. Ototoxische Antibiotika in der Behandlung des Morbus Meniere. *Therapie Woche Wochenschrift Fur Praktische Medizin* 1976;26(20):1–6.
- [5] Beck C, Schmidt CL. 10 years of experience with intratympanally applied streptomycin (gentamicin) in the therapy of morbus Meniere. *Arch Otorhinolaryngol* 1978;221(2):149–52.
- [6] Katzke D. [Treatment of Meniere's disease with intratympanically applied gentamicin sulphate]. *Laryngol Rhinol Otol (Stuttg)* 1982;61(1):4–8.
- [7] Blessing RE, Schlenter WW. [Long-term results of gentamicin therapy of Meniere's disease]. *Laryngorhinootologie* 1989;68(12):657–60.
- [8] Moller C, Odkvist LM, Thell J, et al. Vestibular and audiologic functions in gentamicin-treated Meniere's disease. *Am J Otol* 1988;9(5):383–91.
- [9] Odkvist LM. Middle ear ototoxic treatment for inner ear disease. *Acta Otolaryngol Suppl* 1989;457:83–6.
- [10] Laitakari K. Intratympanic gentamicin in severe Meniere's disease. *Clin Otolaryngol* 1990; 15(6):545–8.
- [11] Nedzelski JM, Schessel DA, Bryce GE, et al. Chemical labyrinthectomy: local application of gentamicin for the treatment of unilateral Meniere's disease. *Am J Otol* 1992;13(1):18–22.
- [12] Nedzelski JM, Bryce GM, Pfeleiderer AG. Treatment of Meniere's disease with topical gentamicin: a preliminary report. *J Otolaryngol* 1992;21:95–101.

- [13] Nedzelski JM, Chiong CM, Fradet G, et al. Intratympanic gentamicin instillation as treatment of unilateral Meniere's disease: update of an ongoing study. *Am J Otol* 1993;14(3): 278–82.
- [14] Kaplan DM, Nedzelski JM, Chen JM, et al. Intratympanic gentamicin for the treatment of unilateral Meniere's disease. *Laryngoscope* 2000;110(8):1298–305.
- [15] Monsell EM, Balkany TA, Gates GA, et al. Committee on Hearing and Equilibrium guidelines for the diagnosis and evaluation of therapy in Meniere's disease. *Otolaryngol Head Neck Surg* 1995;113:181–5.
- [16] Kaplan DM, Nedzelski JM, Al Abidi A, et al. Hearing loss following intratympanic instillation of gentamicin for the treatment of unilateral Meniere's disease. *J Otolaryngol* 2002;31(2):106–11.
- [17] Magnusson M, Padoan S. Delayed onset of ototoxic effects of gentamicin in treatment of Meniere's disease. Rationale for extremely low dose therapy. *Acta Otolaryngol* 1991;111(4): 671–6.
- [18] Magnusson M, Padoan S, Karlberg M, et al. Delayed onset of ototoxic effects of gentamicin in treatment of Meniere's disease. *Acta Otolaryngol Suppl (Stockh)* 1991;481:610–2.
- [19] Toth AA, Parnes LS. Intratympanic gentamicin therapy for Meniere's disease: preliminary comparison of two regimens. *J Otolaryngol* 1995;24(6):340–4.
- [20] Atlas J, Parnes LS. Intratympanic gentamicin for intractable Meniere's disease: 5-year follow-up. *J Otolaryngol* 2003;32(5):288–93.
- [21] Blakley BW. Clinical forum: a review of intratympanic therapy. *Am J Otolaryngol* 1997; 18(4):520–6.
- [22] Diamond C, O'Connell DA, Hornig JD, et al. Systematic review of intratympanic gentamicin in Meniere's disease. *J Otolaryngol* 2003;32(6):351–61.
- [23] Smith BM, Myers MG. The penetration of gentamicin and neomycin into perilymph across the round window membrane. *Otolaryngol Head Neck Surg* 1979;87(6):888–91.
- [24] Goycoolea MV. Clinical aspects of round window membrane permeability under normal and pathological conditions. *Acta Otolaryngol* 2001;121(4):437–47.
- [25] Plontke SK, Wood AW, Salt AN. Analysis of gentamicin kinetics in fluids of the inner ear with round window administration. *Otol Neurotol* 2002;23(6):967–74.
- [26] Hibi T, Suzuki T, Nakashima T. Perilymphatic concentration of gentamicin administered intratympanically in guinea pigs. *Acta Otolaryngol* 2001;121(3):336–41.
- [27] Sahni RS, Paparella MM, Schachern PA, et al. Thickness of the human round window membrane in different forms of otitis media. *Arch Otolaryngol Head Neck Surg* 1987;113(6): 630–4.
- [28] Becvarovski Z, Bojrab DI, Michaelides EM, et al. Round window gentamicin absorption: an in vivo human model. *Laryngoscope* 2002;112(9):1610–3.
- [29] Hellstrom S, Johansson U, Anniko M. Structure of the round window membrane. *Acta Otolaryngol Suppl* 1989;457:33–42.
- [30] Alzamil KS, Linthicum FH Jr. Extraneous round window membranes and plugs: possible effect on intratympanic therapy. *Ann Otol Rhinol Laryngol* 2000;109(1):30–2.
- [31] Schachern PA, Paparella MM, Duvall AJ III, et al. The human round window membrane. An electron microscopic study. *Arch Otolaryngol* 1984;110(1):15–21.
- [32] Tran Ba HP, Bernard P, Schacht J. Kinetics of gentamicin uptake and release in the rat. Comparison of inner ear tissues and fluids with other organs. *J Clin Invest* 1986;77(5): 1492–500.
- [33] Balough BJ, Hoffer ME, Wester D, et al. Kinetics of gentamicin uptake in the inner ear of Chinchilla langier after middle-ear administration in a sustained-release vehicle. *Otolaryngol Head Neck Surg* 1998;119(5):427–31.
- [34] Salt AN, Ma Y. Quantification of solute entry into cochlear perilymph through the round window membrane. *Hear Res* 2001;154(1–2):88–97.
- [35] de Groot JC, Meeuwse F, Ruizendaal WE, et al. Ultrastructural localization of gentamicin in the cochlea. *Hear Res* 1990;50(1–2):35–42.

- [36] Kroese AB, Das A, Hudspeth AJ. Blockage of the transduction channels of hair cells in the bullfrog's sacculus by aminoglycoside antibiotics. *Hear Res* 1989;37(3):203–17.
- [37] Steyger PS, Peters SL, Rehling J, et al. Uptake of gentamicin by bullfrog saccular hair cells in vitro. *J Assoc Res Otolaryngol* 2003;4(4):565–78.
- [38] Hashino E, Shero M, Salvi RJ. Lysosomal targeting and accumulation of aminoglycoside antibiotics in sensory hair cells. *Brain Res* 1997;777(1–2):75–85.
- [39] Hashino E, Shero M, Salvi RJ. Lysosomal augmentation during aminoglycoside uptake in cochlear hair cells. *Brain Res* 2000;887(1):90–7.
- [40] Hiel H, Bennani H, Erre JP, et al. Kinetics of gentamicin in cochlear hair cells after chronic treatment. *Acta Otolaryngol* 1992;112(2):272–7.
- [41] Dulon D, Hiel H, Arousseau C, et al. Pharmacokinetics of gentamicin in the sensory hair cells of the organ of Corti: rapid uptake and long term persistence. *C R Acad Sci III* 1993;316(7):682–7.
- [42] Beaubien AR, Karpinski K, Ormsby E. Toxicodynamics and toxicokinetics of amikacin in the guinea pig cochlea. *Hear Res* 1995;83:62–79.
- [43] Takumida M, Wersall J, Bagger-Sjoberg D. Sensory hair fusion and glycocalyx changes after gentamicin exposure in the guinea pig. *Acta Otolaryngol Suppl* 1989;457:78–82.
- [44] Li L, Nevill G, Forge A. Two modes of hair cell loss from the vestibular sensory epithelia of the guinea pig inner ear. *J Comp Neurol* 1995;355(3):405–17.
- [45] Lindeman HH. Regional differences in sensitivity of the vestibular sensory epithelia to ototoxic antibiotics. *Acta Otolaryngol (Stockh)* 1969;67(2):177–89.
- [46] Lopez I, Honrubia V, Lee SC, et al. Quantification of the process of hair cell loss and recovery in the chinchilla crista ampullaris after gentamicin treatment. *Int J Dev Neurosci* 1997;15(4–5):447–61.
- [47] Wanamaker HH, Slepecky NB, Cefaratti LK, et al. Comparison of vestibular and cochlear ototoxicity from transtympanic streptomycin administration. *Am J Otol* 1999;20(4):457–64.
- [48] Chen JM, Kakigi A, Hirakawa H, et al. Middle ear instillation of gentamicin and streptomycin in chinchillas: morphologic appraisal of selective ototoxicity. *J Otolaryngol* 1999;28(3):121–8.
- [49] Zheng JL, Keller G, Gao WQ. Immunocytochemical and morphological evidence for intracellular self-repair as an important contributor to mammalian hair cell recovery. *J Neurosci* 1999;19(6):2161–70.
- [50] Schacht J. Biochemical basis of aminoglycoside ototoxicity. *Otolaryngol Clin North Am* 1993;26(5):845–56.
- [51] Song BB, Sha SH, Schacht J. Iron chelators protect from aminoglycoside-induced cochlear and vestibulo-toxicity. *Free Radic Biol Med* 1998;25(2):189–95.
- [52] Nakagawa T, Yamane H, Shibata S, et al. Gentamicin ototoxicity induced apoptosis of the vestibular hair cells of guinea pigs. *Eur Arch Otorhinolaryngol* 1997;254(1):9–14.
- [53] Prezant TR, Agopian JV, Bohlman MC, et al. Mitochondrial ribosomal RNA mutation associated with both antibiotic-induced and nonsyndromic deafness. *Nat Genet* 1993;4:289–94.
- [54] Hutchin T, Haworth I, Higashi K, et al. A molecular basis for human hypersensitivity to aminoglycoside antibodies. *Nucleic Acids Res* 1993;21(18):4174–9.
- [55] Nakagawa T, Yamane H. Cytochrome c redistribution in apoptosis of guinea pig vestibular hair cells. *Brain Res* 1999;847(2):357–9.
- [56] Bagger-Sjoberg D, Wersall J. Gentamicin-induced mitochondrial damage in inner ear sensory cells of the lizard *Calotes versicolor*. *Acta Otolaryngol (Stockh)* 1978;86(1–2):35–51.
- [57] Bernard C, Ferrary E, Sterkers O. Production of endolymph in the semicircular canal of the frog *Rana esculenta*. *J Physiol (London)* 1986;371:17–28.
- [58] Park JC, Cohen GM. Vestibular ototoxicity in the chick: effects of streptomycin on equilibrium and on ampullary dark cells. *Am J Otolaryngol* 1982;3(2):117–27.
- [59] Park JC, Cohen GM. Further observations of vestibular ototoxicity in the chick: effects of streptomycin on the ampullary sensory epithelium. *Am J Otolaryngol* 1984;5(6):387–93.

- [60] Pender DJ. Gentamicin tympanoclysis: effects on the vestibular secretory cells. *Am J Otolaryngol* 1985;6(5):358–67.
- [61] Weisleder P, Rubel EW. Hair cell regeneration after streptomycin toxicity in the avian vestibular epithelium. *J Comp Neurol* 1993;331(1):97–110.
- [62] Carey JP, Fuchs AF, Rubel EW. Hair cell regeneration and recovery of the vestibuloocular reflex in the avian vestibular system. *J Neurophysiol* 1996;76(5):3301–12.
- [63] Carey JP, Minor LB, Peng GC, et al. Changes in the three-dimensional angular vestibulo-ocular reflex following intratympanic gentamicin for Meniere's disease. *J Assoc Res Otolaryngol* 2002;3(4):430–43.
- [64] Ewald JR. *Physiologische Untersuchungen uber das endorgan des nervus octavus*. Wiesbaden, Germany: Bergmann; 1892.
- [65] Halmagyi GM, Curthoys IS. A clinical sign of canal paresis. *Arch Neurol* 1988;45:737–9.
- [66] Aw ST, Haslwanter T, Halmagyi GM, et al. Three dimensional vector analysis of the human vestibulo-ocular reflex in response to high-acceleration head rotations. I. Responses in normal subjects. *J Neurophysiol* 1996;76(6):4009–20.
- [67] Aw ST, Halmagyi GM, Haslwanter T, et al. Three-dimensional vector analysis of the human vestibulo-ocular reflex in response to high acceleration head rotations. II. Responses in subjects with unilateral vestibular loss and selective semicircular canal occlusion. *J Neurophysiol* 1996;76:4021–30.
- [68] Thomsen J, Bretlau P, Tos M, et al. Placebo effect in surgery for Meniere's disease: a double-blind, placebo-controlled study on endolymphatic sac shunt surgery. *Arch Otolaryngol Head Neck Surg* 1981;107:271–7.
- [69] Minor LB. Intratympanic gentamicin for control of vertigo in Meniere's disease: vestibular signs that specify completion of therapy. *Am J Otol* 1999;20(2):209–19.
- [70] Itoh A, Sakata E. Treatment of vestibular disorders. *Acta Otolaryngol Suppl* 1991;481: 617–23.
- [71] Shea JJ Jr, Ge X. Dexamethasone perfusion of the labyrinth plus intravenous dexamethasone or Meniere's disease. *Otolaryngol Clin North Am* 1996;29(2):353–8.
- [72] Barrs DM, Keyser JS, Stallworth C, et al. Intratympanic steroid injections for intractable Meniere's disease. *Laryngoscope* 2001;111(12):2100–4.
- [73] Langman AW, Kemink JL, Graham MD. Titration streptomycin therapy for bilateral Meniere's disease. Follow-up report. *Ann Otol Rhinol Laryngol* 1990;99(11):923–6.
- [74] Balyan FR, Taibah A, De Donato G, et al. Titration streptomycin therapy in Meniere's disease: long-term results. *Otolaryngol Head Neck Surg* 1998;118(2):261–6.
- [75] Pyykko I, Ishizaki H, Kaasinen S, et al. Intratympanic gentamicin in bilateral Meniere's disease. *Otolaryngol Head Neck Surg* 1994;110:162–7.
- [76] Brantberg K, Bergenius J, Tribukait A. Gentamicin treatment in peripheral vestibular disorders other than Meniere's disease. *ORL J Otorhinolaryngol Relat Spec* 1996;58:277–9.
- [77] Dieterich M, Brandt T. Episodic vertigo related to migraine (90 cases): vestibular migraine? *J Neurol* 1999;246(10):883–92.
- [78] Neuhauser H, Leopold M, von Brevern M, et al. The interrelations of migraine, vertigo, and migrainous vertigo. *Neurology* 2001;56(4):436–41.
- [79] Radtke A, Lempert T, Gresty MA, et al. Migraine and Meniere's disease: is there a link? *Neurology* 2002;59(11):1700–4.
- [80] Vass Z, Steyger PS, Hordichok AJ, et al. Capsaicin stimulation of the cochlea and electric stimulation of the trigeminal ganglion mediate vascular permeability in cochlear and vertebro-basilar arteries: a potential cause of inner ear dysfunction in headache. *Neuroscience* 2001;103(1):189–201.
- [81] Blakley BW. Update on intratympanic gentamicin for Meniere's disease. *Laryngoscope* 2000;110(2 Pt 1):236–40.
- [82] Wu IC, Minor LB. Long-term hearing outcome in patients receiving intratympanic gentamicin for Meniere's disease. *Laryngoscope* 2003;113(5):815–20.